

Case report

Hematometra in a young Poongsan dog with continuous vulvar hemorrhage

Hyun-Sik Kim, Ill-Hwa Kim, Hyun-Gu Kang*

Veterinary Medical Center, College of Veterinary Medicine, Chungbuk National University, Cheongju 28644, Korea

Hematometra is defined as the accumulation of blood and blood clots in the uterus. An 8-month-old, intact female Poongsan dog presented with continuous severe hemorrhagic vulvar discharge and anemia. The initial diagnostic evaluation included abdominal ultrasonography, radiography, and physical and laboratory examinations. The electrolyte levels were low: Na ion levels were 128 mmol/L (reference range, 141 - 152 mmol/L), and Cl ion levels were 99 mmol/L (reference range, 105 - 115 mmol/L). At presentation, the white blood cell count was $60.19 \times 10^3/\mu\text{L}$ (reference range, $5.05 - 16.76 \times 10^3/\mu\text{L}$), packed cell volume was 11.8% (reference range, 37.3% - 61.7%), hemoglobin levels were 4.6 g/dl (reference range, 13.1 - 20.5 g/dl), and platelet count was $48 \times 10^3/\mu\text{L}$ (reference range, $148 - 484 \times 10^3/\mu\text{L}$). Based on the results of the complete blood count, the dog was given lactated Ringer's solution and a whole blood transfusion. On abdominal ultrasonography, the left uterine horn was enlarged and filled with echogenic fluid. On laparotomy, the uterus was enlarged and showed an accumulation of blood and blood clots. The incised uterine horn revealed that the endometrium was filled with blood and blood clots and had a cystic appearance. Additionally, thick and yellowish pus had accumulated in the uterine cavity. Gross findings revealed a definitive diagnosis of cystic endometrial hyperplasia-pyometra complex with severe hemorrhage, termed hematometra. This case was the first report of severe hematometra in a young Poongsan dog.

Key words: Poongsan dog, pyometra, hematometra, hemorrhage, CEH

Introduction

Canine uterine diseases such as cystic endometrial hyperplasia (CEH), mucometra, hydrometra, and pyometra are common in countries where neutering healthy dogs

are not generally practiced [1]. Mucometra, hydrometra, and pyometra are defined by the type of fluid present in the uterus and the degree of mucin hydration [2]. Hematometra, in which the uterine content is hemorrhagic, is rarely reported [3]. By definition, pyometra is the accumulation of pus within the uterine lumen, typically occurring during or immediately following a period of high progesterone levels [4].

Clinically, a bitch with pyometra may present with lack of appetite, depression, polydipsia, lethargy, abdominal distension, and possible vaginal discharge [5]. Symptoms of pyometra are classified by the patency of the uterine cervix. Closed-cervix pyometra is a medical emergency that requires rapid intervention to prevent sepsis and potential death [5].

The diagnosis of canine uterine disease is best made with ultrasonography and radiology [6]. Pyometra presents as an enlarged uterus with convoluted tubular horns filled with anechoic to echogenic fluid, in which case movement, characterized by slow and swirling patterns, is often noted; mucometra and hydrometra, however, present with thin uterine walls and echogenic or anechoic fluid, respectively [7]. In hematometra, complete blood count and serum chemistry results can vary. Mild normocytic, normochromic, and nonregenerative anemia often develops secondary to chronic disease and generally resolves following treatment [3]. In hematometra, physical examination findings and clinical signs are inconclusive, but the bitch can suffer from anemia with frank vulvar hemorrhage of an open-cervix type. A diagnosis of hematometra is not made until a laparotomy is performed and gross findings are assessed.

Although pyometra can occur at every age, cases of pyometra or hematometra complex in a young dog have not been previously reported. This case describes CEH-pyometra/hematometra in a young Poongsan dog.

*Corresponding author: Hyun-Gu Kang,

College of Veterinary Medicine, Chungbuk National University, Cheongju 28644, Korea
Tel: +82-43-261-3359, Fax: +82-43-261-3224, E-mail: kang6467@cbu.ac.kr

Case Report

An 8-month-old, intact female Poongsan dog presented with severe, continuous hemorrhagic vulvar discharge and anemia. Hemorrhagic vulvar discharge was continued for 5 days before presentation. The initial diagnostic evaluation included abdominal ultrasonography, radiography, and physical and laboratory examinations. An activated partial thromboplastin time test was performed to rule out a coagulation disorder. Because of the severe anemia and dehydration, blood cross-matching was performed in anticipation of a blood transfusion.

The electrolyte levels were low: Na and Cl ion levels were lower than the normal reference range (Table 1). However, alkaline phosphatase (ALP) levels were much higher than the normal reference range. At presentation, a complete blood cell count was performed, revealing a white blood cell (WBC) count of $60.19 \times 10^3/\mu\text{L}$ (reference range, $5.05\text{-}16.76 \times 10^3/\mu\text{L}$), a packed cell volume (PCV) of 11.8% (reference range, 37.3%-61.7%), a hemoglobin level of 4.6 g/dL (reference range, 13.1-20.5 g/dL), and a platelet count of $48 \times 10^3/\mu\text{L}$ (reference range, $148\text{-}484 \times 10^3/\mu\text{L}$) (Table 2). These laboratory results corresponded to a recent hemorrhagic episode. On the basis of the laboratory results and patient history, we performed a whole blood transfusion on day 0 (day of presentation). Additionally, metronidazole (15 mg/kg, IV,

BID, TRIZELE Inj[®]; JW Pharmaceutical Co., Ltd.) and cefotaxime (50 mg/kg, IV, TID, CEFOTAXIMENARI-UM[®]; Wooridul Pharmaceutical Co., Ltd.) were administered for vaginal and systemic infections, respectively. Because of continuous vaginal hemorrhage, cimetidine (10 mg/kg, IV, BID, H-2 Inj[®]; JW Pharmaceutical Co., Ltd.), vitamin K (2.5 mg/kg, SC, TID, VITAMIN K1 Inj[®]; Dae Han Pharm Co., Ltd.), vitamin B (0.3 mL/body, IV, SID, BEECOMHEXA Inj[®]; Yuhan Co., Ltd.), taurine (3 mL/body, IV, BID, TARUINE-F Inj[®]; Samyang Anipharma Co., Ltd.), and desmopressin (1 $\mu\text{g}/\text{kg}$, SC, Once, MINIRIN Inj[®]; Ferring Pharmaceuticals Korea Inc.) were administered for anemia. On day 2, laboratory results showed abnormalities: the WBC ($60.19 \times 10^3/\mu\text{L}$) was higher than the normal reference range, the PCV was 16.3%, the hemoglobin level was 5.4 g/dL, and the platelet count was $102 \times 10^3/\mu\text{L}$. The PCV, hemoglobin level, and platelet count were all lower than the normal reference range. Because of the sustained decline in PCV, the bitch was given a whole blood transfusion over 6 h.

On abdominal ultrasonography, an enlarged uterus was observed. The left uterine horn was enlarged and filled with echogenic fluid. Its diameter was approximately 3 cm. An anechoic cyst and echogenic mass were seen in the uterine wall and uterine cavity, respectively (Fig. 1).

Based on patient history, physical examination, abdominal ultrasonography, radiography, and laboratory examination, the dog was diagnosed with pyometra, mucometra, hydrometra, and hematometra. For surgical

Table 1. Electrolyte and serum chemistry during treatment in a Poongsan dog with hematometra

Parameters	Reference value	Value		
		Day 0	Day 2	Day 3
Na	141-152 mmol/L	128*	142	141
K	3.6-5.8 mmol/L	3.6	3.2*	2.9*
Cl	105-115 mmol/L	99*	118**	113
Ca	9-11.3 mg/dl	8.7*	8.6*	8.7*
P	2.6-6.2 mg/dl	4.4	4.2	3.4
Total Protein	5.4-7.1 g/dl	4.5*	3.5*	4.1*
Albumin	2.6-3.3 g/dl	1.8*	1.5*	2.2*
Globulin	2.7-4.4 g/dl	2.7	2.0*	1.9*
ALT	21-102 IU/L	9*	-	86
BUN	7-25 mg/dl	16.7	7.6	4.1*
Creatinine	0.5-1.5 mg/dl	0.7	0.6	0.6
ALP	29-97 IU/L	241**	-	180**

ALT: alanine aminotransferase; BUN: blood urea nitrogen; ALP: alkaline phosphatase. *: lower than reference range, **: higher than reference range. Ovariohysterectomy was operated on second day following presentation. Day 0 = presented day.

Table 2. Complete blood cell count during treatment in a Poongsan dog with hematometra

Parameters	Reference value	Value			
		Day 0	Day 2	Day 3	Day 6
WBC	$5.05\text{-}16.76 \times 10^3/\mu\text{L}$	60.19^{**}	44.49^{**}	68.2^{**}	11.43
Monocyte	3-14 %	2.2*	10.5	3.7	8.5
Lymphocyte	12-30 %	8.3*	8.4*	3.9*	20.5
Neutrophil	60-80 %	87.5^{**}	80.4^{**}	91.7^{**}	67.3
Eosinophil	2-10 %	2.0*	0.7*	0.6*	3.7
PCV	37.3-61.7 %	11.8*	16.3*	22.7*	29.1*
Hemoglobin	13.1-20.5 g/dl	4.6*	5.4*	7.8*	9.1*
Platelet	$148\text{-}484 \times 10^3/\mu\text{L}$	48*	102*	170	338

WBC: white blood cell; RBC: red blood cell; PCV: packed cell volume; *: lower than reference range, **: higher than reference range. Ovariohysterectomy was operated on second day following presentation. Day 0 = presented day.

treatment, an ovariectomy was performed. Tramadol (3 mg/kg, IV, TID, MARITROL Inj[®]; Jeil Pharm. Co. Ltd.), cefotaxime (50 mg/kg, IV, TID), metronidazol (10 mg/kg, IV, BID), and cimetidine (10 mg/kg IV, BID) were administered preoperatively. The bitch was anesthetized by inhalation of isoflurane. Propofol (PROVIVE[®] Inj; 10 mg/mL, Myungmoon Pharm) was administered intravenously until the lack of jaw tone, gagging reflex, and coughing reflex was observed. After these reflexes disappeared, an endotracheal tube was inserted. Anesthesia was maintained with isoflurane (TERRELLTM, Piramal Critical Care, Bethlehem).

At laparotomy, the uterus was enlarged and filled with fluid; evidence of hemorrhage was present (Fig. 2). Postoperatively, the uterine horn was incised, revealing an

accumulation of blood clots. The endometrium contained blood and blood clots and had a cystic appearance. Additionally, thick and yellowish pus had accumulated in the uterine cavity. The diameter of the uterine horn was approximately 3 cm and was filled with cyst, pus, and blood clots (Fig. 3). The incised uterine horn contained a cyst. Gross findings revealed a definitive diagnosis of cystic endometrial hyperplasia-pyometra complex with severe hemorrhage, termed hematometra.

Postoperatively, we prescribed tramadol (3 mg/kg, IV, TID), cefotaxime (50 mg/kg, IV, QID), cimetidine (10 mg/kg, IV, BID), metronidazol (15 mg/kg, IV, BID), vitamin B (0.3 mL/body, IV, BID), vitamin K (2 mg/kg, SC, TID), and taurine (3 mL/body, IV, BID). The bitch was maintained on IV fluids (normal saline 0.9%, 35 mL/h

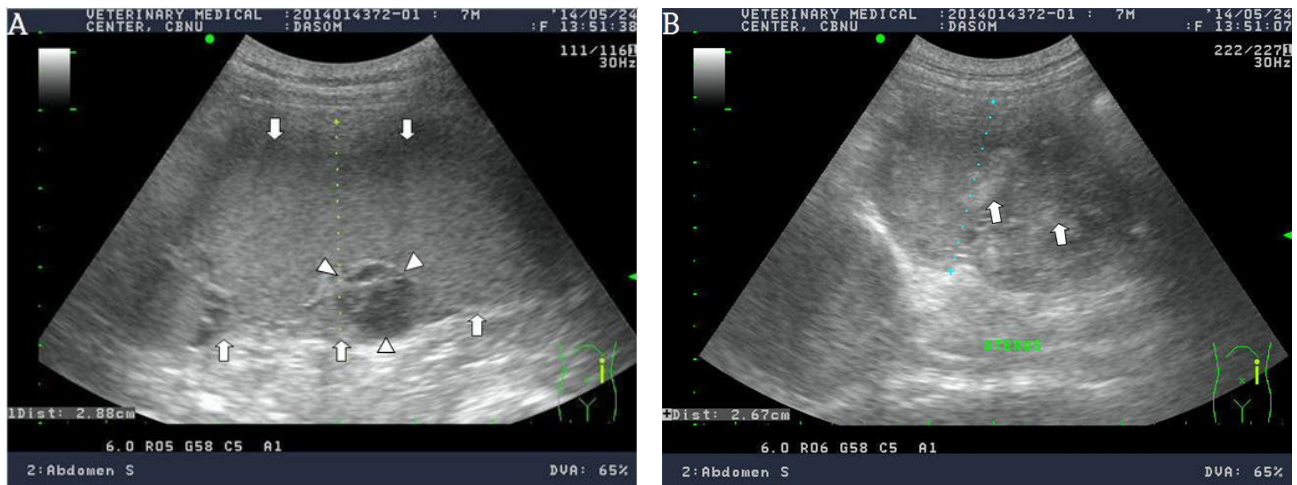


Fig. 1. Ultrasonographic images of the left uterine horn. (A) Sagittal image of the left uterine horn. The left uterine horn was enlarged and filled with echogenic fluid, which proved to be blood (arrows). An anechoic cyst was seen in the uterine wall (arrow heads). (B) Sagittal image of the uterine horn containing an echogenic mass (arrows). A 5-10 MHz multi-convex transducer was used.

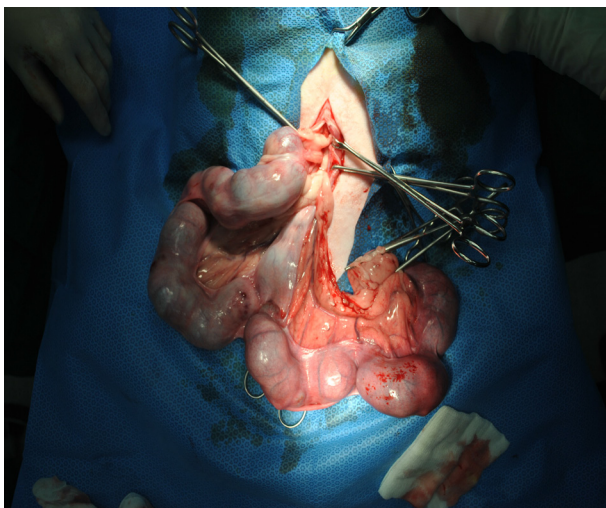


Fig. 2. Photograph of the extracted uterus from the abdominal cavity during laparotomy.

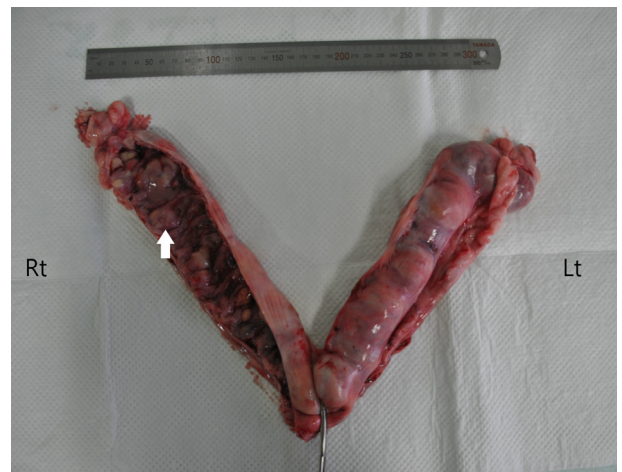

Fig. 3. Gross lesion in the removed uterus. The uterus was enlarged with a uterine horn diameter of approximately 3 cm. The incised right uterine cavity contained a cyst, pus, and blood clots (arrow).

and albumin 30 mL/h). In addition, antibiotics (metronidazol, 15 mg/kg, IV, BID, and cefotaxime, 50 mg/kg, IV, QID) were administered for 2 days. The patient showed normal condition at the last follow-up, 7 days postoperatively.

Discussion

Jindo and Poongsan dogs are the most popular breeds in Korea. Poongsan dogs are commonly used for hunting and are a representative native breed in North Korea [8]. Canine CEH-pyometra complex is a commonly diagnosed disease of the reproductive system but can be life-threatening [9-11]. Hematometra is rare among cases of CEH-pyometra complex. Pyometra is typically considered a disease of intact, middle-aged bitches, but it can occur in younger dogs [19]. In this case, Poongsan dog developed CEH-pyometra complex at 8-month-old, which is younger than previously reported [3, 12-14].

Hematometra is regarded as an emergency because early diagnosis and rapid therapeutic intervention are necessary to prevent a fatal outcome [1]. Differential diagnosis of mucometra, hydrometra, hematometra, and pyometra can be made based on cytological examination, complete blood count, serum chemistry analysis, urinalysis, and ultrasonography [15]. In the present case, cytological examination, complete blood count, serum chemistry analysis, and ultrasonography were performed for the differential diagnosis of mucometra, hydrometra, hematometra, and pyometra.

Hematometra and metrorrhagia are uncommon clinical presentations [3]. Reported etiologies include postpartum subinvolution of placental sites [16, 17], anticoagulant rodenticide toxicity [18] and other acquired coagulation deficiencies, uterine trauma, neoplasia [19, 20], placental necrosis, congenital coagulation deficiency [15], idiopathic prepubertal metrorrhagia [21], postpartum endometritis [8], and uterine serosal inclusion cysts [22]. Therefore, a differential diagnosis according to these etiologies should be performed. In the present case, these diseases were ruled out by thorough laboratory and physical examinations.

Symptom onset of pyometra in dogs is gradual and insidious [23]. Generally, clinical signs include vomiting, abdominal distension, dehydration, anorexia, and polyuria/polydipsia [23-25]. In the present case, clinical signs included vomiting, anorexia, depression, dehydration, and continuous hemorrhage.

When hematometra is suspected, ovariohysterectomy should be performed as soon as possible due to life-threatening complications associated with bacteremia and endotoxemia [3]. Bitches who are seriously ill should be medically stabilized with appropriate intravenous fluid therapies and broad-spectrum antibiotics prior to surgery

[5]. A whole blood transfusion should be performed for bitches with severe anemia. In the present case, the dog received a whole blood transfusion to correct the severe anemia prior to surgery, and intravenous fluids were administered to address the dehydration. Subsequently, an ovariohysterectomy was performed. After surgery, gross findings revealed that one part of the uterine lumen was filled with blood clots and that another part of the uterine lumen was filled with pus. Further, the endometrium contained many cysts. The bitch was finally diagnosed with concurrent pyometra and hematometra. This case describes evidence of hematometra with severe vulvar hemorrhage in a young Poongsan dog.

ORCID

Hyun-Gu Kang, <http://orcid.org/0000-0002-3827-6112>

References

- Hagman R. Diagnostic and prognostic markers for uterine diseases in dogs. *Reprod Domest Anim* 2014; 49: 16-20.
- Dow C. The cystic hyperplasia-pyometra complex in the bitch. *J Comp Pathol* 1959; 69: 237-250.
- Troxel MT, Cornetta AM, Pastor KF, Hartzband LE, Besancon MF. Severe hematometra in a dog with cystic endometrial hyperplasia/pyometra complex. *J Am Anim Hosp Assoc* 2002; 38(1): 85-89.
- Baithalu RK, Maharana BR, Mishra C, Sarangi L, Samal L. Canine pyometra. *Veterinary World* 2010; 3(7): 340-342.
- Smith FO. Canine pyometra. *Theriogenology* 2006; 66(3): 610-612.
- Bigliardi E, Parmigiani E, Cavirani S, Luppi A, Bonati L, Corradi A. Ultrasonography and cystic hyperplasia-pyometra complex in the bitch. *Reprod Domest Anim* 2004; 39(3): 136-140.
- Nak D, Nak Y, Tuna B. Follow-up examinations after medical treatment of pyometra in cats with the progesterone-antagonist aglepristone. *J Feline Med Surg* 2009; 11(6): 499-502.
- Cho GJ. Microsatellite polymorphism and genetic relationship in dog breeds in Korea. *Asian-Aust J Anim Sci* 2005; 18: 1071-1074.
- Borresen B. Pyometra in the dog. II.-A pathophysiological investigation. II. Anamnestic, clinical and reproductive aspects. *Nord Vet Med* 1979; 31: 251-257.
- Okano S, Tagawa M, Takase K. Relationship of the blood endotoxin concentration and prognosis in dogs with pyometra. *J Vet Med Sci* 1998; 60: 1265-1267.
- Purvis D, Kirby R. Systemic inflammatory response

- syndrome: septic shock. *Vet Clin North Am Small Anim Pract* 1994; 24: 1225-1247.
12. Dow C. The cystic hyperplasia-pyometra complex in the bitch. *J Comp Pathol* 1959; 69: 237-250.
 13. Gibson A, Dean R, Yates D, Stavisky J. A retrospective study of pyometra at five RSPCA hospitals in the UK: 1728 cases from 2006 to 2011. *Vet Rec* 2013; 173: 396.
 14. Niskanen M, Thrusfield MV. Associations between age, parity, hormonal therapy and breed, and pyometra in Finnish dogs. *Vet Rec* 1998; 143: 493-498.
 15. Wheeler SL, Weingand KW, Thrall MA, Berg RJ, Schwarz PD, Olson PN. Persistent uterine and vaginal hemorrhage in a beagle with factor VII deficiency. *J Am Vet Med Assoc* 1984; 185: 447-448.
 16. Arbeiter K. The use of progestins in the treatment of persistent uterine hemorrhage in the postpartum bitch and cow: a clinical report. *Theriogenology* 1975; 4(1): 11-13.
 17. Dickie MB, Arbeiter K. Diagnosis and therapy of the subinvolution of placental sites in the bitch. *J Reprod Fertil (Suppl)* 1993; 47: 471-475.
 18. Padgett SL, Stokes JE, Tucker RL, Wheaton LG. Hematometra secondary to anticoagulant rodenticide toxicity. *J Am Anim Hosp Assoc* 1998; 34(5): 437-439.
 19. Gotthelf LN. An unusual case of recurrent hematuria. *Vet Med* 1997; 92: 734-736.
 20. Malm C, Ferreira HI, Nascimento EF, Chow Castillo LA. Clinical and histopathological study of ovarian and uterine alterations of bitches under ovariohysterectomy. *Arq Bras Med Vet Zootoc* 1994; 46: 13-18.
 21. Joshi BP, Humor A. Prepubertal metrorrhagia in bitches: a case study. *Indian Vet J* 1991; 68: 879-880.
 22. Arnold S, Hubler M, Hauser B, Kaser-Hotz B, Rüschi P. Uterine serosal inclusion cysts in a bitch. *J Small Anim Pract* 1996; 37(5): 235-237.
 23. Verstegen J, Dhaliwal G, Verstegen-Onclin K. Mucometra, cystic endometrial hyperplasia, and pyometra in the bitch: advances in treatment and assessment of future reproductive success. *Theriogenology* 2000; 70: 364-374.
 24. Asheim A. Pathogenesis of renal damage and polydipsia in dogs with pyometra. *J Am Vet Med Assoc* 1965; 147: 736-745.
 25. DeSchepper J, DeCock I, Capiou E. Urinary gamma-glutamyl transferase and the degree of renal dysfunction in 75 bitches with pyometra. *Res Vet Sci* 1989; 46: 396-400.